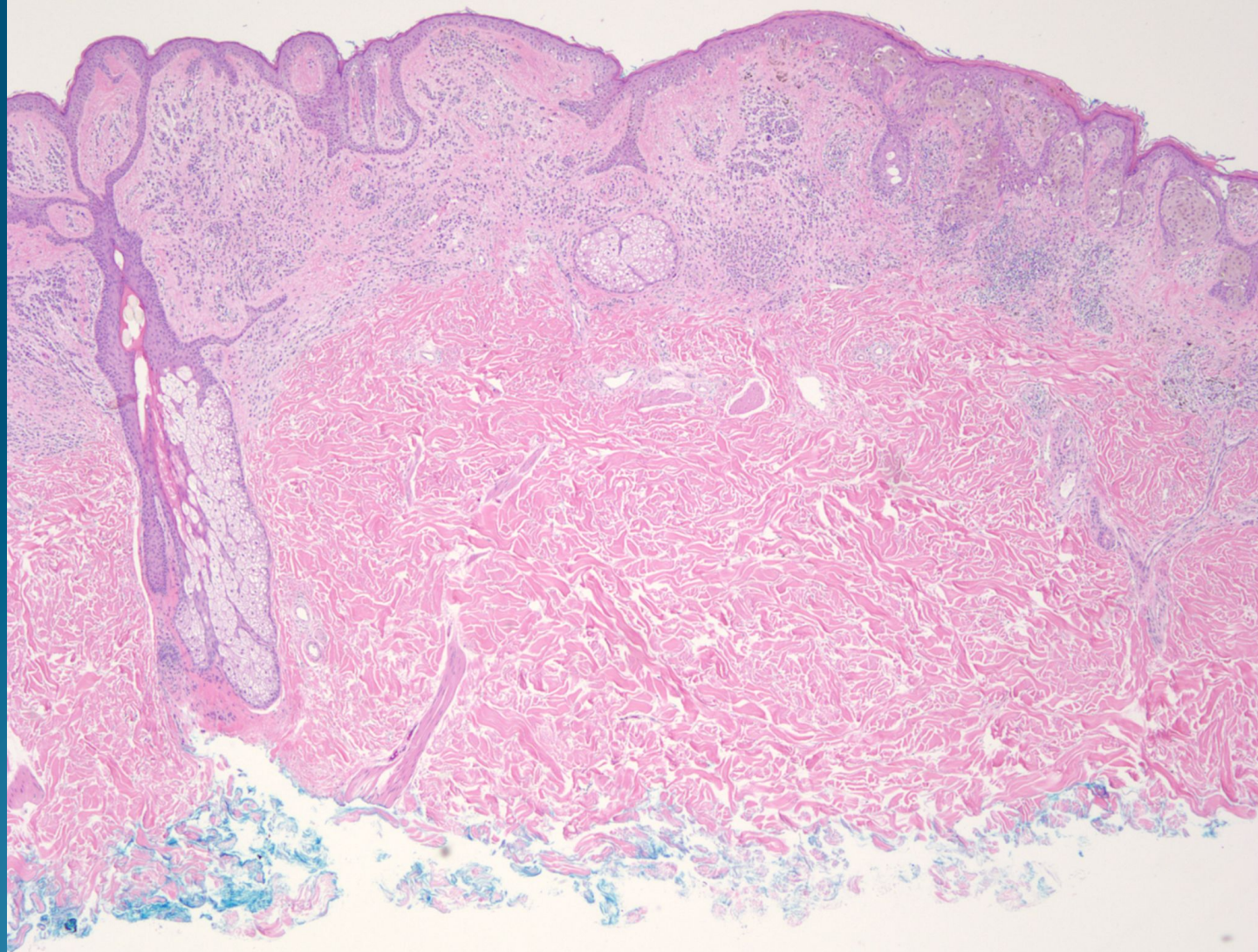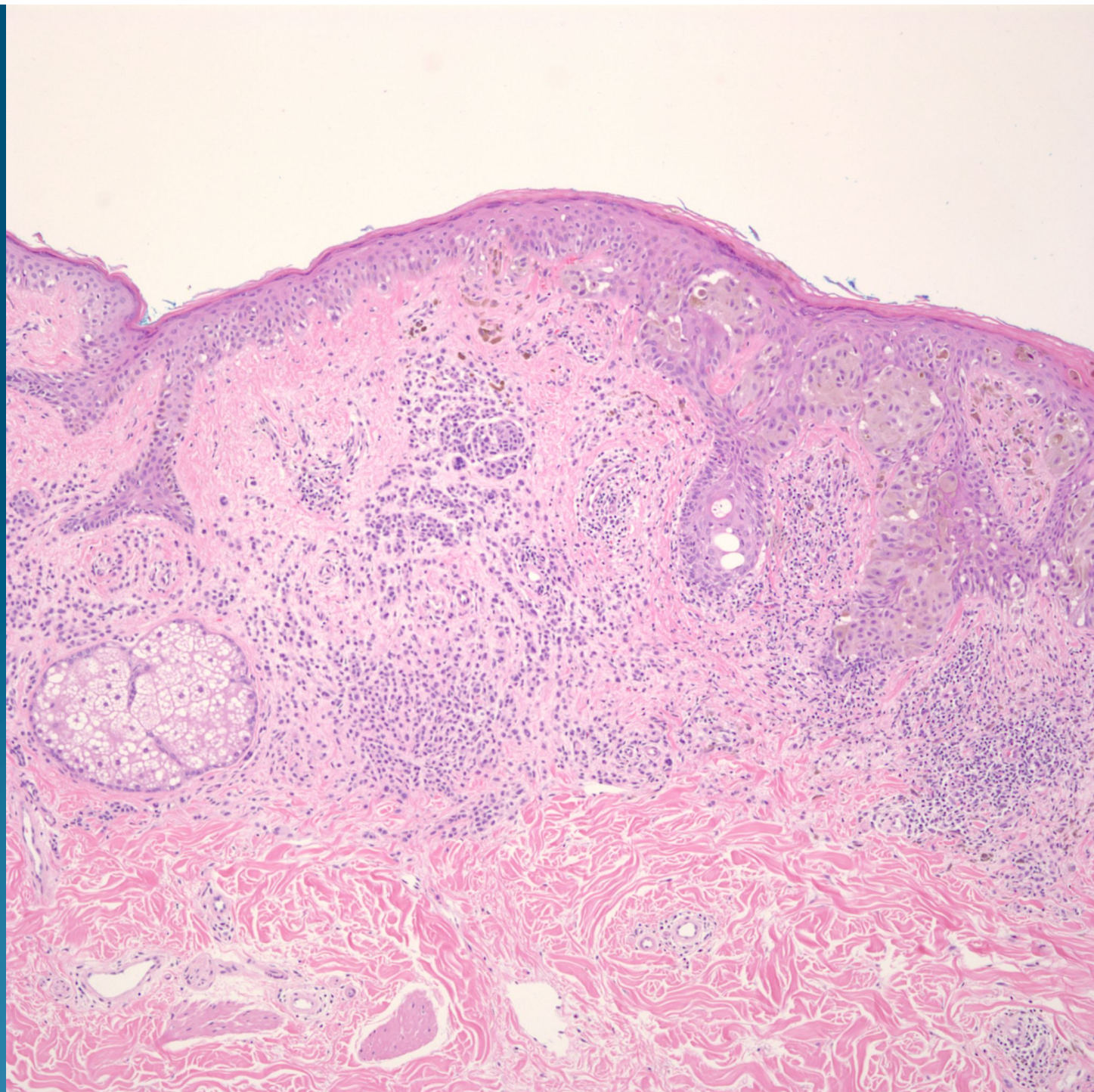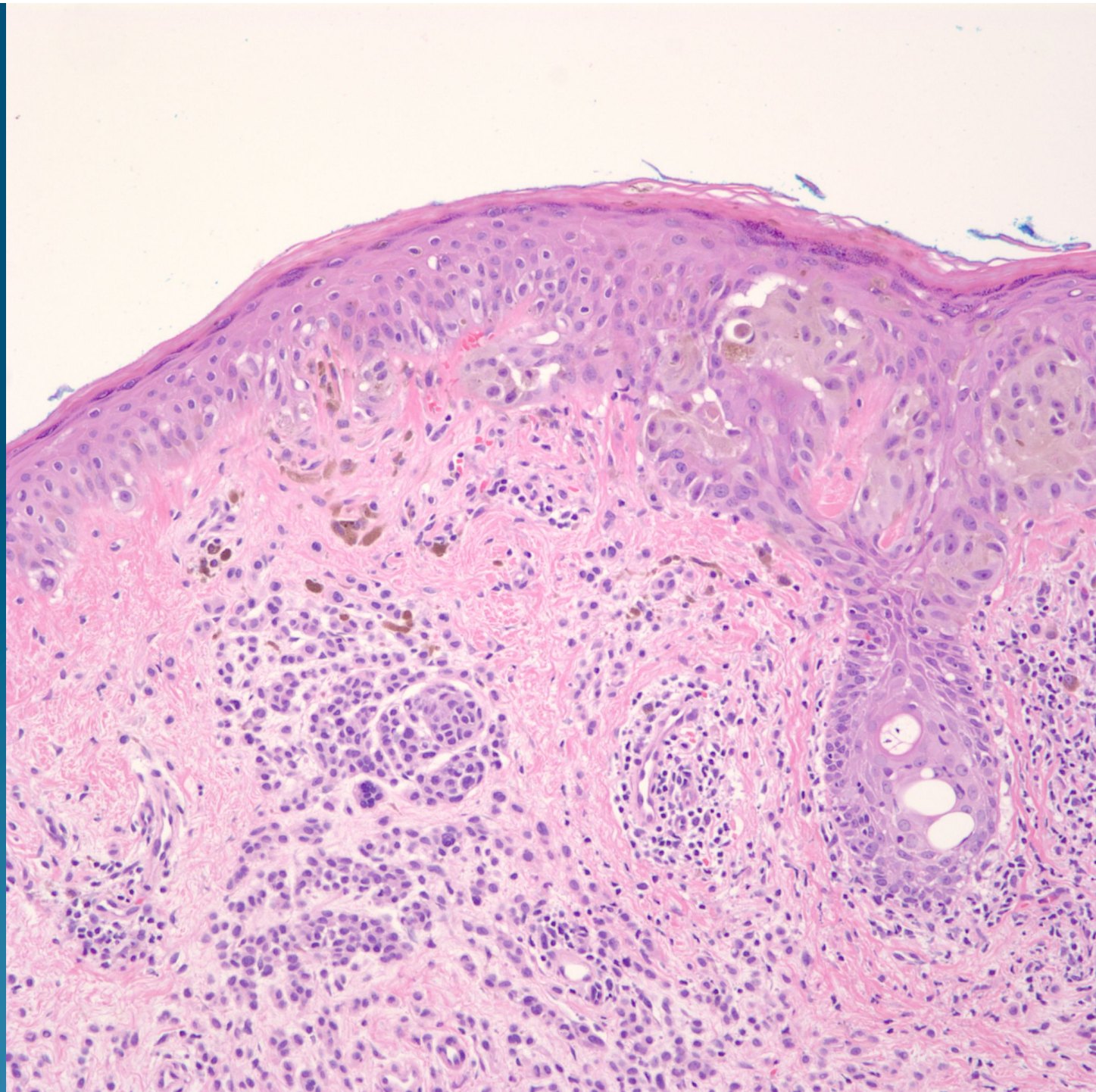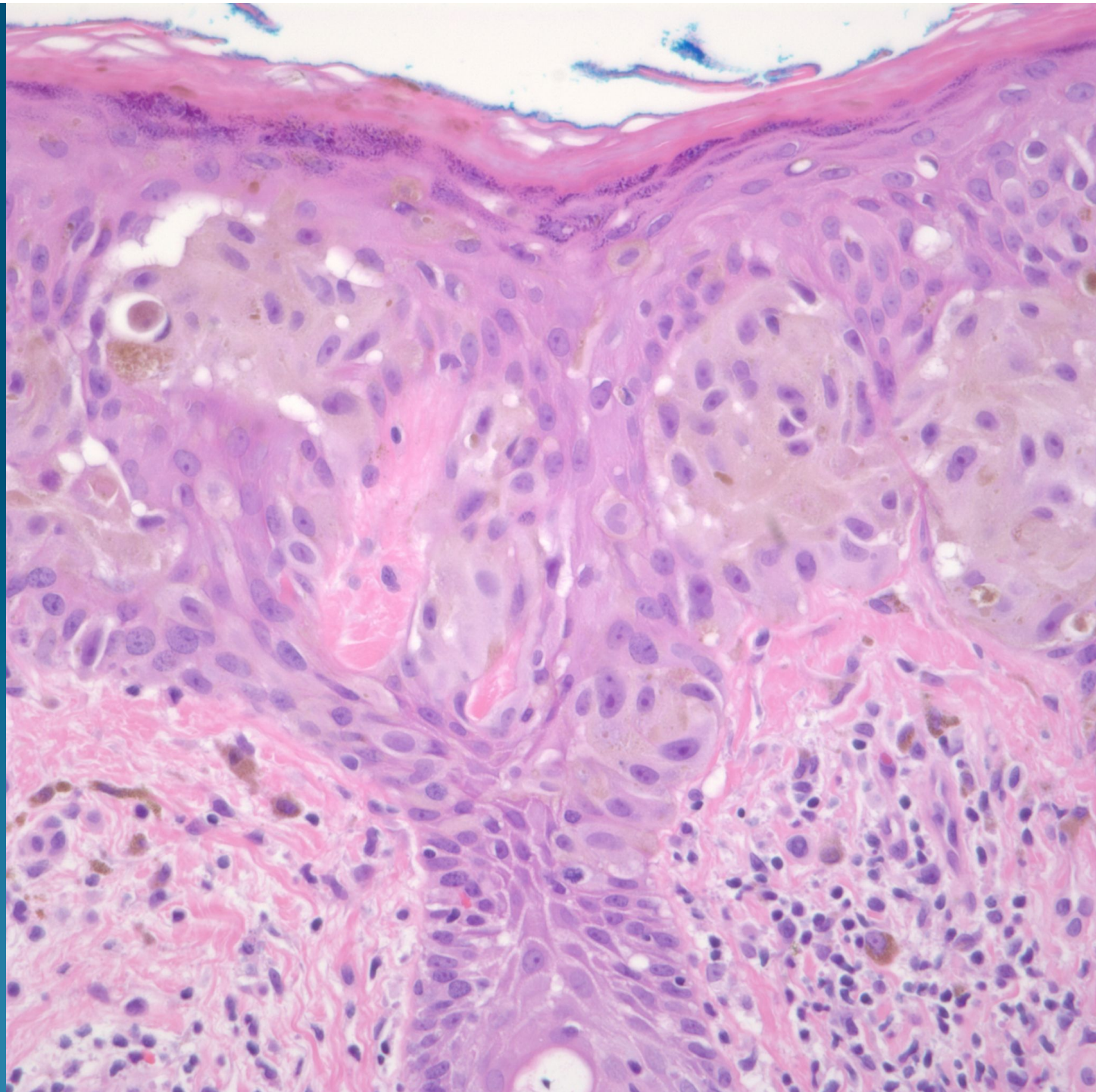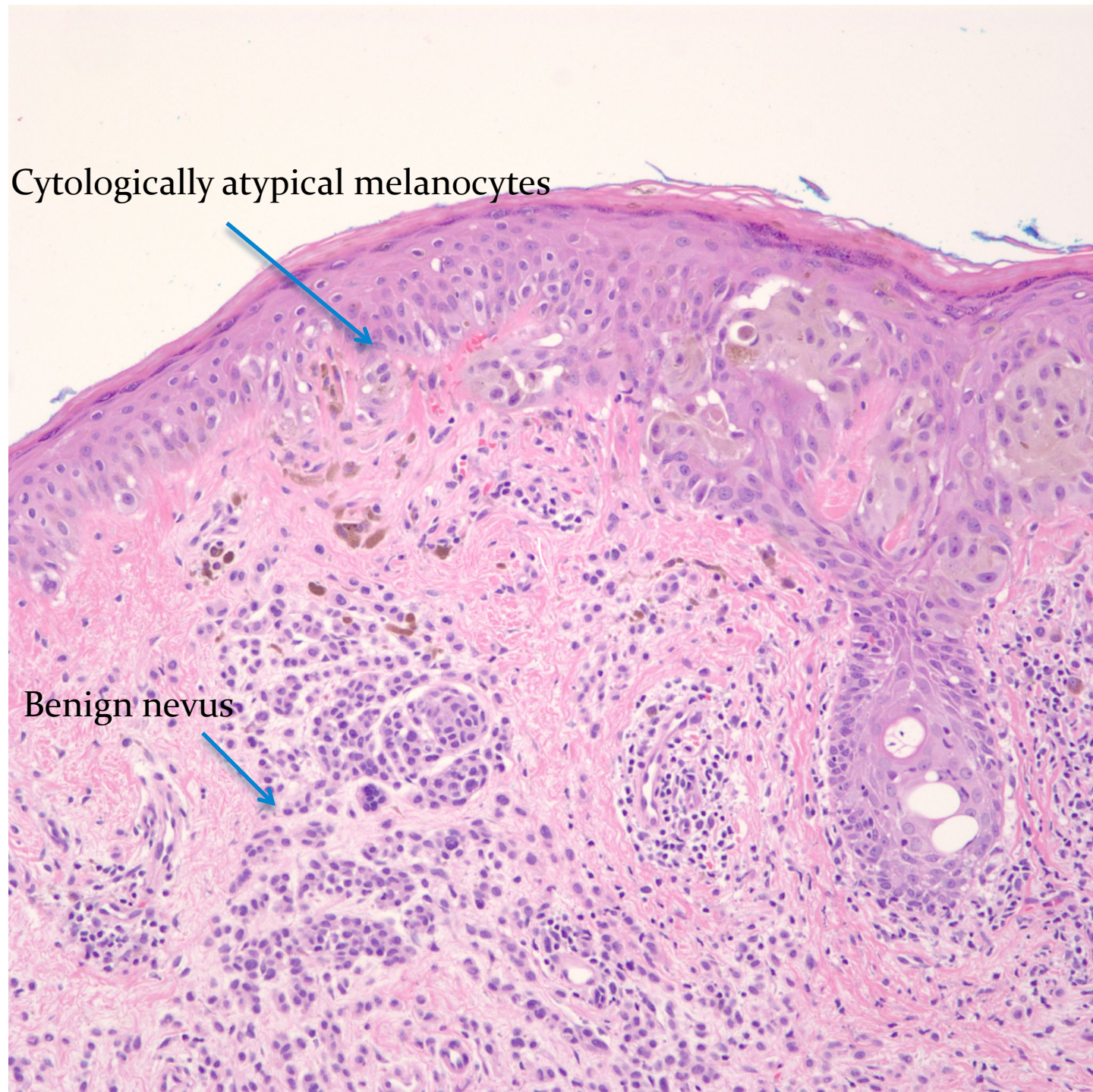


Melanoma in situ arising with an
intradermal melanocytic nevus

Cytologically atypical melanocytes



Benign nevus